



PRESENTING CLINICAL SIGNS

History: Coughing that has not responded to doxycycline and hydrocodone.

DATE

3/27/23

ECHOCARDIOGRAPHIC FINDINGS

2D, M-mode, and Doppler study.

PERFORMED BY:

Kelly Vazquez

INTERPRETED BY

Keith Blass, DVM,
MS, DACVIM
(Cardiology)

Left atrial size is normal. The mitral valve leaflets are mildly thickened, and a mild jet of eccentric mitral regurgitation is present. Left ventricular dimensions are normal. Left ventricular systolic function is mildly hyperdynamic. The aorta and aortic valve are normal. Right atrial and right ventricular dimensions are normal. The tricuspid valve appears normal, though trace tricuspid regurgitation is present. The pulmonary artery and pulmonic valve are normal. No shunting lesions are visualized. No heartworms are visualized. No pericardial effusion or cardiac masses are seen.

PATIENT

Buddy Monteyne

LA - 32.7 mm
LVIDd - 32.8 mm
LVIDs - 18.6 mm
FS - 43%
RA - 20.8 mm
LVOT - 1.50 m/s
RVOT - 1.22 m/s

ASSESSMENT/RECOMMENDATIONS

Degenerative mitral valve disease

SPECIES

Canine

This examination demonstrates mild regurgitation of blood across Buddy's mitral valve resulting from degenerative valve disease. The hemodynamic effects of the regurgitation also appear to be mild, as Buddy does not have secondary dilation of either of his left heart chambers, and his left ventricular systolic function is well-preserved. As such, Buddy's mitral valve disease appears to be well-compensated, and it does not appear that his cough is cardiogenic in origin.

BREED

Shih Tzu

Thoracic radiographs are recommended to further evaluate Buddy's cough.

SEX

No therapy is recommended at this stage of disease.

MN

A recheck echocardiogram is recommended in 6 months to monitor for disease progression.

AGE

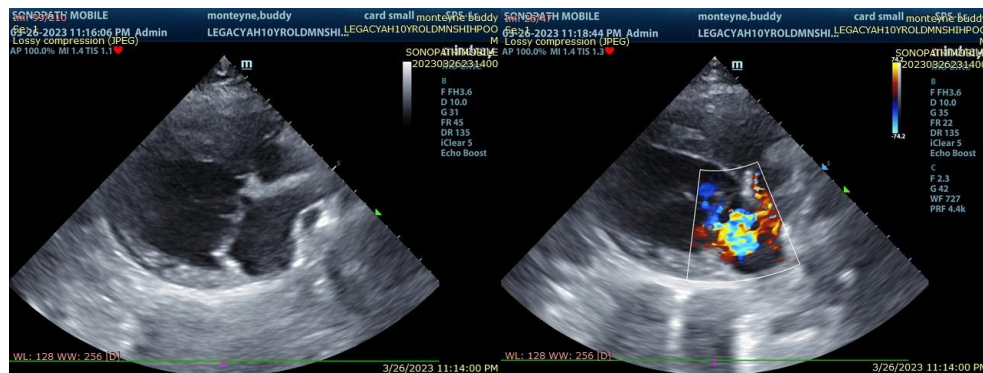
10 y

WEIGHT

26.7 lb

HOSPITAL NAME

Legacy AH



REFERRING VET

The information and recommendations provided are based on the images presented by the referring veterinarian. No evaluation can be communicated regarding pathology that was not



visible in the image/video clips provided.

DATE Thank you for this referral. If the clinical or image interpretation does not parallel your findings or if I can be of any further assistance please contact me.

3/27/23

PERFORMED BY: Keith Blass, DVM, MS, DACVIM (Cardiology)
KeithBlass@gmail.com
631-804-5754

Kelly Vazquez

INTERPRETED BY

Keith Blass, DVM,
MS, DACVIM
(Cardiology)

PATIENT

Buddy Monteyne

SPECIES

Canine

BREED

Shih Tzu

SEX

MN

AGE

10 y

WEIGHT

26.7 lb

HOSPITAL NAME

Legacy AH

REFERRING VET